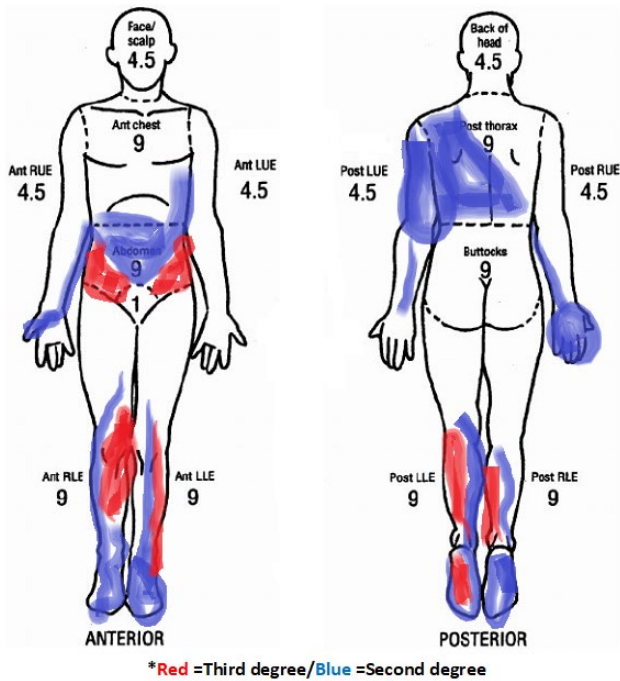


Patient D

- Healthy 28-year-old male
- Intubated
- Vital signs stable
- Circumferential burns to lower left leg



Patient H

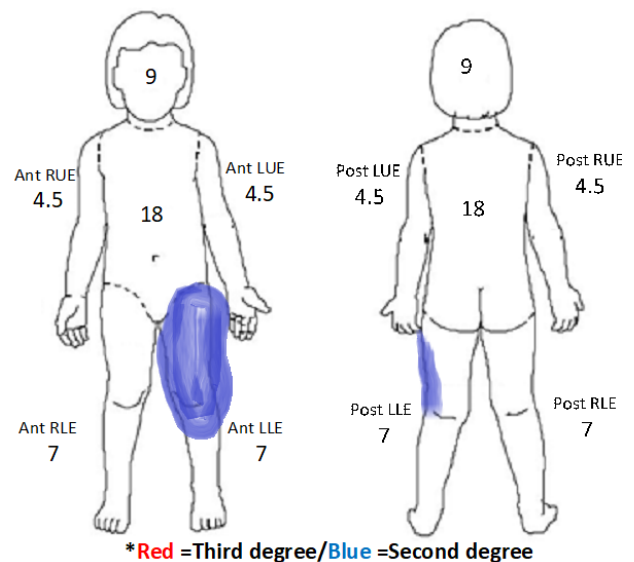
- Healthy 7 year-old-female
- Fractured wrist
- Vitals stable
- Crying loudly, unable to locate mother

Patient I

- 33 year-old-female
- Multiple abrasions to face
- Laceration to neck, bleeding controlled
- Ambulatory

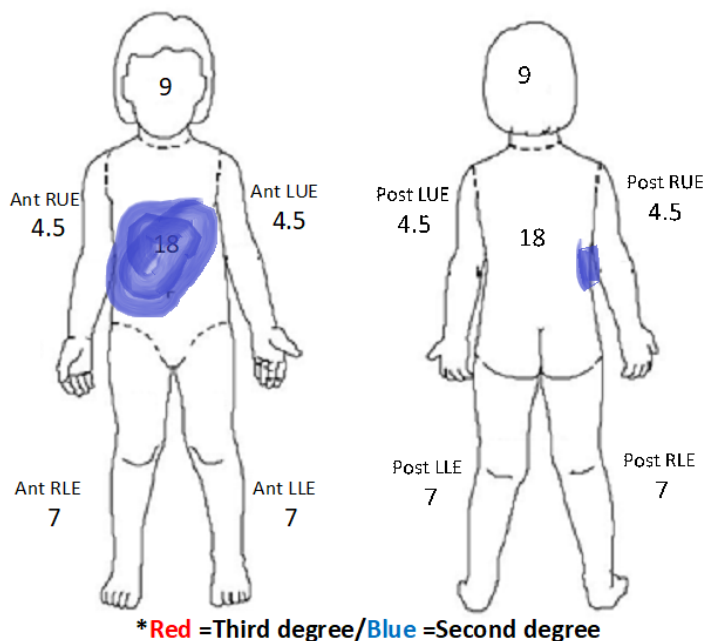
Patient N

- 8 year old-male
- 5% TBSA (per initial EMS assessment)
- Alert and oriented
- Ambulatory



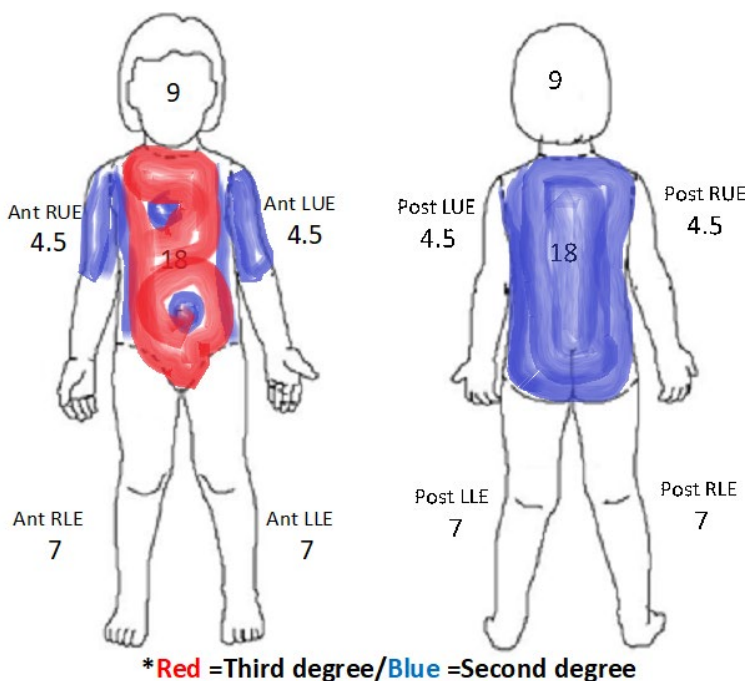
Patient Q

- 10 year-old-female
- Burns to part of abdomen
- Age appropriate



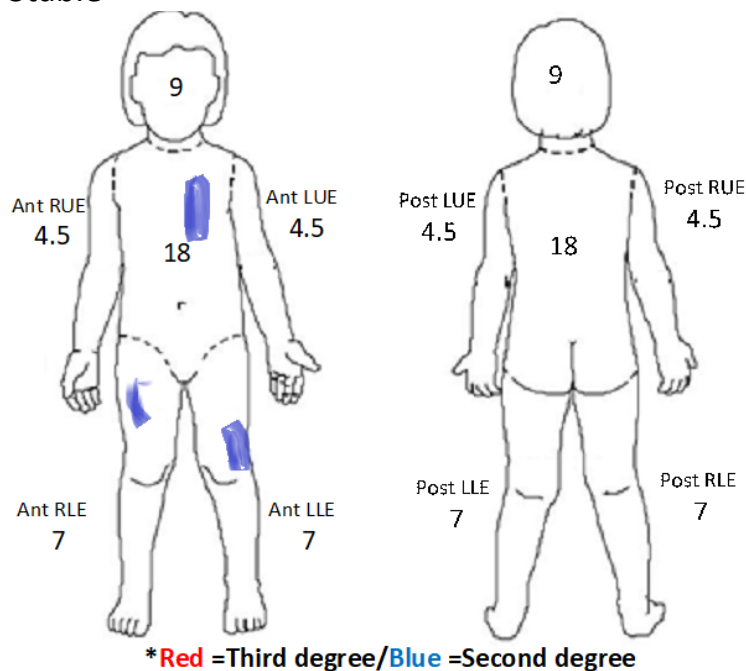
Patient AD

- 13 year-old-female
- Unconscious
- 40% TBSA (per initial EMS assessment)
- Family Spanish speaking only



Patient AE

- 10 year-old-female
- Abrasions to face
- Broken fingers to right hand
- Alert and ambulatory

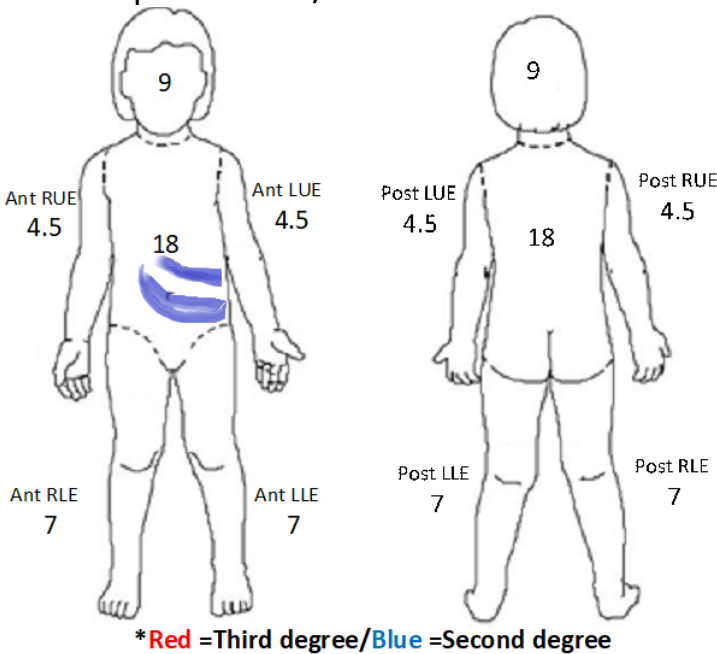


Patient AI

- 6 year-old-male
- Laceration to right forearm
- 3% TBSA (per initial EMS assessment)
- Stable

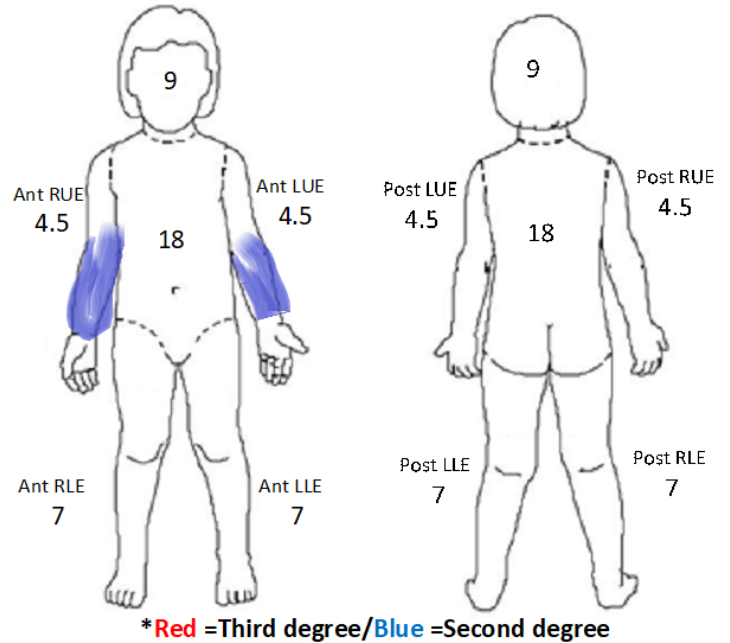
Patient AM

- 8 year-old-female
- 5% TBSA (per initial EMS assessment)
- Respirations 20/min



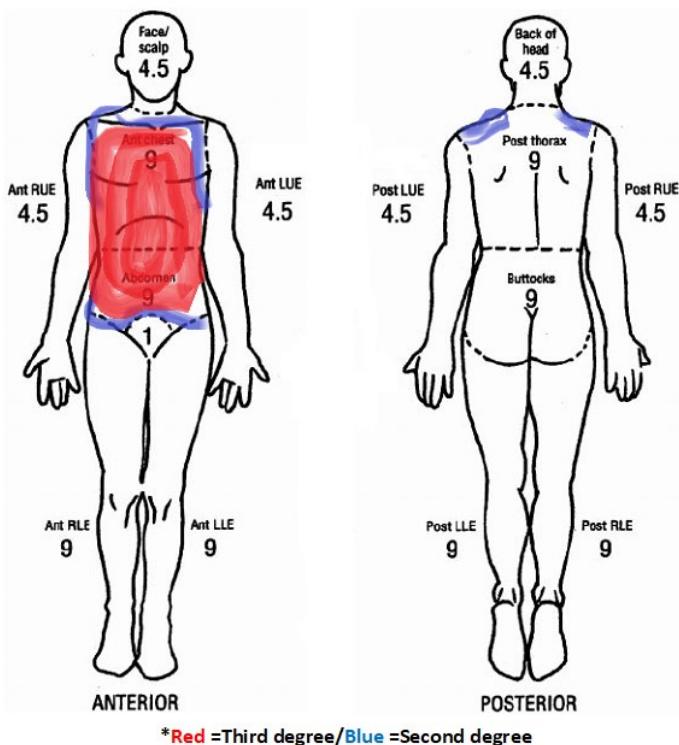
Patient AP

- 5 year-old-female
- 5% TBSA (per initial EMS assessment)
- Mother Spanish speaking only
- Vitals stable



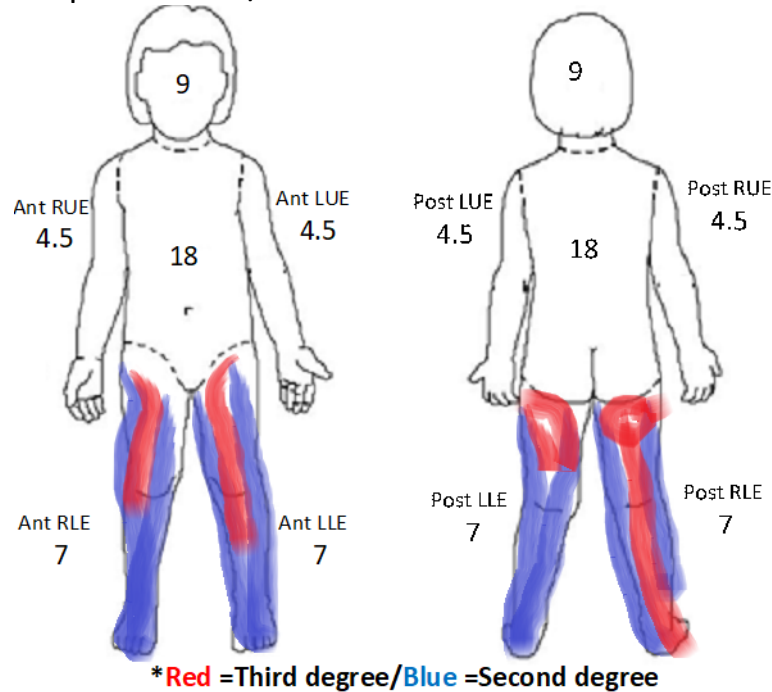
Patient AU

- 38 year-old-female
- 18% TBSA (per initial EMS assessment)
- Open fracture to left lower leg
- Unable to stand/walk



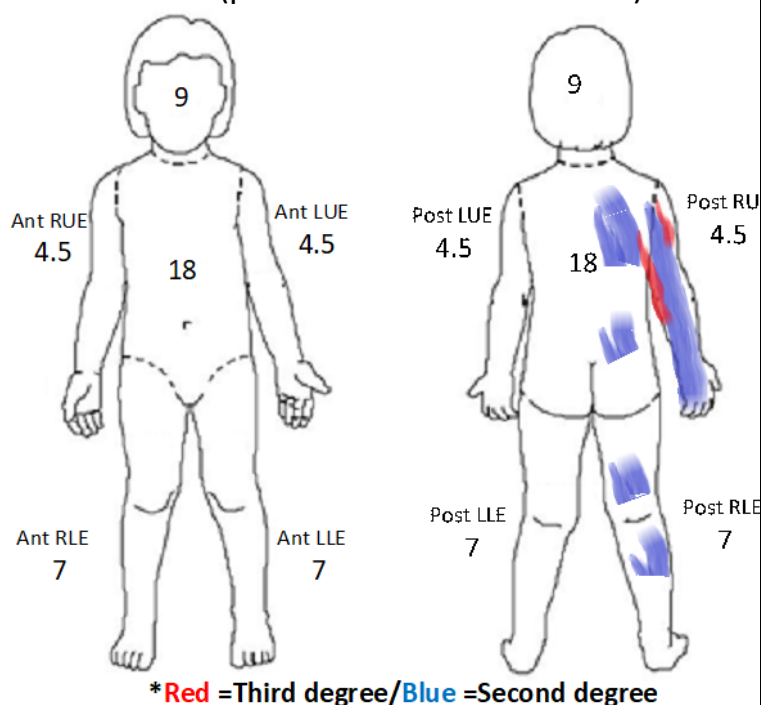
Patient AV

- 5 year-old male
- 28% TBSA (per initial EMS assessment)
- Respirations 35/min



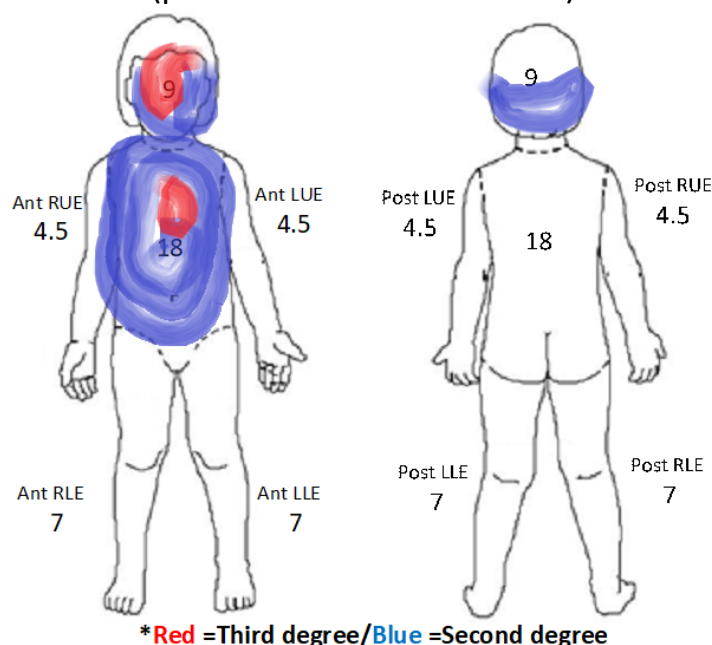
Patient AZ

- 14 year-old-male
- Compound fracture to right leg
- 10% TBSA (per initial EMS assessment)



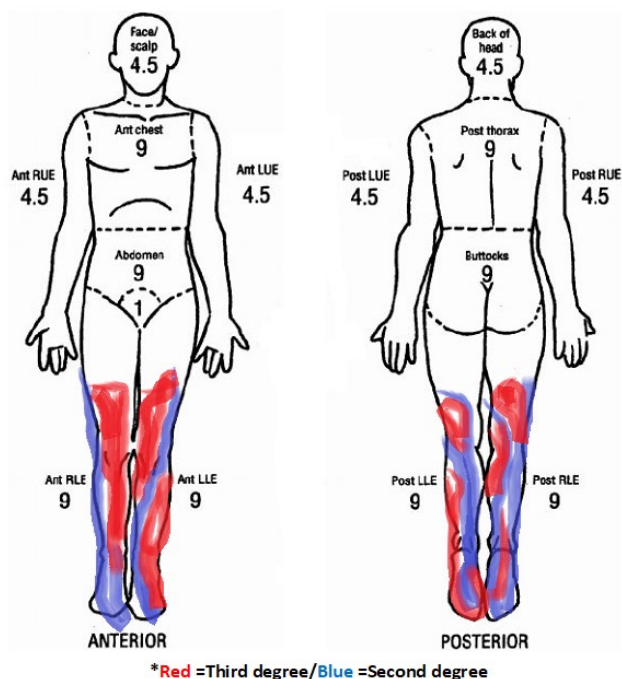
Patient BC

- 3 year-old-male
- Unconscious
- 30% TBSA (per initial EMS assessment)



Patient BE

- 18 year-old-male
- 35% TBSA (per initial EMS assessment)
- Vitals stable
- Alert and oriented
- Non-ambulatory



Patient BF

- 7 year-old-male
- 4% TBSA (per initial EMS assessment)
- Ambulatory but somewhat unsteady gait

